

Hepatoprotective efficacy of *Grewia asiatica* fruit against oxidative stress in swiss albino mice

K.V. Sharma* and R. Sisodia

Radiation Biology Laboratory, Department of Zoology, University of Rajasthan, Jaipur, Rajasthan, 302055, India

Background: The radioprotective effect of *Grewia asiatica* fruit (GAE) which contains anthocyanin type cyanidin 3- glucoside, vitamin C, A, minerals, carotenes and dietary fibers etc was studied. **Materials and Methods:** For study Swiss albino mice were divided into five groups-1. Control (vehicle treated) 2. GAE treated (700 mg / Kg. b.wt / day for fifteen days), 3. Irradiated (5 Gy), 4. GAE + Irradiated and 5. Irradiated + GAE treated. **Results:** The irradiation of animals resulted in a significant depletion in the DNA and RNA level at all intervals studied viz 1-30 days in comparison to control group. Treatment of mice with GAE before and after irradiation caused a significant elevation in liver DNA and RNA level in comparison to irradiated mice. Photomicrograph of liver histology also showed that pre and post supplementation of GAE provides protection against radiation. Similarly counting of different type hepatocytes also showed that GAE protect the liver against radiation. **Conclusion:** Thus biochemical and histopathological results proves that GAE has the potential against radiation. **Iran. J. Radiat. Res., 2010; 8 (2): 75-85**

Keywords: Radioprotection, mice liver, DNA, RNA, liver histology, hepatocyte count.

INTRODUCTION

Radiation causes tissue injury, both in tumors and in normal tissues, by induction of apoptosis or clonogenic cell death triggered by free radical-mediated DNA damage⁽¹⁾. Interaction of ionizing radiation with the biological system results in the generation of many highly reactive short-lived reactive oxygen species (ROS), mainly due to the hydrolysis of water⁽²⁾. These ROS then attack cellular macromolecules like DNA, RNA, proteins, membranes etc, causing their dysfunction and damage⁽³⁾. Saint George⁽⁴⁾ stated that though DNA constitutes only 1% of total cellular mass, any damage to this molecule may lead to highly modified cell fate. DNA is, therefore

referred to as 'Critical molecule' in the event of radiation exposure.

More than half of cancer patients are treated with radiation therapy. Despite its high therapeutic index, radiation therapy can cause disabling injuries to normal tissues, especially in long-term survivors. Thus, one of the great challenges of modern radiation therapy is to increase tolerance of normal tissue to ionizing radiation in order to improve the quality of life of cancer survivors and/or enhance local control using dose escalation. The physiopathological aspects of normal tissue toxicity have been widely explored; however, none of these descriptive findings has led to the development of effective therapeutic strategies⁽⁵⁾.

Naturally occurring antioxidants may provide an extended window of protection against low-dose, low-dose-rate irradiation, including therapeutic potential when administered after irradiation. A number of phytochemicals, including caffeine, genistein and melatonin, have multiple physiological effects, as well as antioxidant activity, which result in radioprotection *in vivo*⁽⁶⁾.

In this context *Grewia asiatica* (Phalsa) cultivated on a commercial scale mainly in the northern and western states of India^(7, 8), is known for its medicinal properties⁽⁹⁾. *Grewia asiatica* contains anthocyanin type cyanidin 3- glucoside vitamin C, A, minerals, carotenes and dietary fibers etc⁽¹⁰⁾. Earlier studies in laboratory showed that supplementation of *Grewia asiatica* fruit

*Corresponding author:

Dr. Krishna V Sharma,
Radiation Biology Laboratory, Department of Zoology,
University of Rajasthan, Jaipur, Rajasthan, 302055,
India.

E-mail: sharma.krishna.v@gmail.com

extract (GAE) can ameliorate radiation induced depletion in GSH and protein level and can inhibit the radiation induced lipid peroxidation in brain ⁽¹¹⁾, cerebrum ^(12, 13), liver ^(14, 15), and blood ⁽¹⁶⁾, and dose reduction factor (DRF) of GAE is 1.53 ⁽¹⁷⁾. Sharma and Sisodia ⁽¹⁸⁾ also showed the radioprotective efficacy of GAE in mice testis in terms of nucleic acid and antioxidant level.

The present study has been undertaken to assessing the histological evidence of radioprotective efficacy of GAE in liver along with its efficacy to protect DNA and RNA damage in liver of Swiss albino mice.

MATERIALS AND METHODS

Animal care and handling

The animal care and handling was done according to the guidelines set by World Health Organization, Geneva, Switzerland and INSA (Indian National Science Academy, New Delhi, India). The Departmental Animal Ethical Committee (DAEC) approved this study. Swiss albino mice (6–8 weeks) old weighing 23±2 gm from an inbred colony was used for the present study. These animals were maintained under controlled conditions of temperature and light (Light: dark, 10 hrs: 14 hrs.). Four animals were housed in a polypropylene cage containing sterile paddy husk (procured locally) as bedding throughout the experiment. They were provided standard mice feed (procured from Hindustan Levers Ltd., India) and water *ad libitum*.

Extract preparation (Drug)

Fresh fruits of *Grewia asiatica* collected locally in summer season were washed, shade dried and powdered after removal of seeds. Methanolic extract was then prepared by refluxing for 48 hours (4×12) at 40°C. The extract thus obtained was vacuum evaporated so as to get in powdered form. The extract was redissolved in double-distilled water (DDW) just before the oral administration. For the various concentrations, a known amount of GAE was

suspended in DDW and 50 µl of GAE suspension was given to each mouse by oral gavage as given by Ahaskar *et al.* ⁽¹⁷⁾.

Biochemical assay for in vivo radioprotective efficacy

Source of irradiation

The cobalt teletherapy unit (ATC-C9) at Cancer Treatment Center, Radiotherapy Department, SMS Medical College and Hospital, Jaipur, Rajasthan, India was used for irradiation. Unanaesthetized animals were restrained in well-ventilated perspex box and whole body exposed to gamma radiation at a distance (SSD) of 77.5cm from the source to deliver the dose rate of 1.07 Gy/ min.

Dose selection

Dose selection of *Grewia asiatica* was carried out on the basis of drug tolerance study in our laboratory ^(17, 19). Various doses of *Grewia asiatica* (100, 400, 700, 1000, 1300 mg/kg b.wt.) were tested against gamma irradiation (10Gy). Thus, 700-mg/kg b.wt. /day was used as optimum dose based on survivability of mice for further experimentation.

Experimental design

Mice selected from an inbred colony were divided into 4 groups (30 animals in each group).

1. Control (vehicle treated): Mice of this group received only DDW water for 15 days.
2. GAE treated: Mice of this group were administered orally once daily with GAE (700mg/kg of b.wt. /day) for 15 consecutive days.
3. Irradiated: Mice received DDW (volume equal to *Grewia asiatica* solution) for 15 days and were than whole body exposed to 5Gy of gamma-radiation.
4. GAE treated + Irradiated: In this group after oral administration of GAE (700mg/kg of b.wt. /day) for 15 consecutive days as done in GAE treated group. Mice were whole body exposed to single dose of 5 Gy gamma-radiation one hour after admini-

stration of last dose of GAE,

5. Irradiated +GAE treated: In this group, after whole body exposure to a single dose of 5 Gy gamma-radiation, oral administration of GAE (700mg/kg of b.wt. /day) was made once daily for 15 consecutive days one hour after radiation exposure.

Six mice from each group were necropsied by cervical dislocation at various intervals viz. 1, 3, 7, 15 and 30 days post irradiation. Liver was used to estimate various changes in biochemical parameters viz. DNA, RNA content, qualitative and quantitative study of liver histology.

DNA estimation assay

DNA was quantified by the method described by Ceriotti (20). Liver was dissected out and homogenate was prepared in glacial distilled water (10 mg/ml). 2 ml homogenate was taken in a centrifuge tube and 1 ml indole reagent was added in it. Then, 1 ml concentrated HCl was added. There after chloroform treatment was given. The water layer from the organic layer was separated out by centrifugation. The intensity of yellow colour lift at green filter against blank was measured out. The volume of DNA from graph was calculated and then the quantity of DNA of tissue was calculated in μ /mg tissue.

RNA estimation assay

RNA was quantified by the method described by Ceriotti (21). Liver was dissected out and homogenate was prepared in glacial distilled water (10 mg/ml). Reaction mixture contains 5 ml H homogenate + 5 ml orcinol + 5 ml Isoamyl alcohol. The upper coloured layer was separated with the help of vacuolizer and the intensity was measured against red filter. The concentration of RNA from standard graph was calculated and then the amount of RNA of tissue was calculated in μ /mg tissue.

Histopathological studies

The samples were fixed in 10% neutral buffered formalin and were processed for

making paraffin blocks and sections 5 μ m thick were cut. The sections of tissues were passed through a graded series of alcohol and stained in Eosin and Harris Haematoxylin (22). Counting normal, binucleate and abnormal cell population with respect to total hepatocytes made quantitative studies. These cells were counted by using a planimeter at high magnification (400x).

Statistical analysis

The results obtained in the present study were expressed as mean \pm SEM. The statistical difference between various groups were analysed by the Student's *t*-test and the significance was observed at the $p < 0.001$, $p < 0.01$ and $p < 0.05$ level.

RESULTS

Statistically non significant difference existed in DNA content between the control and only GAE treated mice. Irradiation caused continuous decrease in DNA content till day 15 p.i. and became 69% in comparison to control thereafter DNA content increased by 3.5% and became 73.56% at day 30 p.i. i.e. 27% deficit still existed from control. Pre/post GAE supplementation after irradiation protects the radiation induced deficit in DNA content specially at day 30 where it is approximately 15% and 19% raised in group IV and V respectively compared to group III. The result indicated that GAE post treatment shows more protection than pre treatment at later intervals i.e. 15 and 30 day p.i. Although the values of DNA content could not achieve the normal levels (figure 1). One-way ANOVA comparison between four groups i.e. control, IR, GAE + IR and IR + GAE group, at each autopsy intervals showed highly significant differences in DNA content of liver on day 1 ($F_{3,20}=36.85$, $p < 0$), day 3 ($F_{3,20}=22.409$, $p < 0$), day 7 ($F_{3,20}=25.165$, $p < 0$), day 15 ($F_{3,20}=20.253$, $p < 0$) and day 30 ($F_{3,20}=14.772$, $p < 0.0000$) p.i. respectively.

No significant change in RNA was seen between GAE treated and control group. Whereas radiation significantly ($p < 0.001$) produced deficit at all the autopsy intervals in comparison to control. GAE pre and post treatment provided protection against radiation by keeping the values higher than irradiated group and at day 30 p.i., statistically significant ($p < 0.001$) differences were seen between irradiated and the experimental group. One-way ANOVA comparison between four groups i.e. control, IR, GAE + IR and IR + GAE group, at each autopsy intervals showed highly significant differences in RNA content of liver on day 1 ($F_{3,20}=3.791$, $p < 0.265$), day 3 ($F_{3,20}=9.168$, $p < 0.0005$), day 7 ($F_{3,20}=19.958$, $p < 0$), day 15 ($F_{3,20}=18.686$, $p < 0$) and day 30 ($F_{3,20}=9.138$, $p < 0.0005$) p.i. respectively.

In the present study, the liver photomicrograph of irradiated mice showed radiolisions in the form of dilated sinusoidal spaces, cellular oedema, hydropic degeneration, hyperemia, lymphocytic infiltration, degranulated and vacuolated cytoplasm, swollen Kupffer's cells, giant cells and

multinucleated cells, large number of binucleated hepatocytes, enucleated cells and necrotic cells along with many pyknotic nuclei. Whereas photomicrograph of liver of GAE pre and post treated irradiated mice showed lesser damage compare to irradiated mice. At day 30, in the experimental group almost normal hepatic architecture as well as mild cytoplasmic vacuolation and some pyknotic, shrunken nuclei and binucleated cells were evident in photomicrograph.

The percentage of normal hepatocytes population diminished after irradiation; the number decreased significantly and progressively till day 7 p.i. After a depression of nearly 36% of normal on day 7, the percentage of normal hepatocytes improved till day 30 and became 81.91% of control level. Initial loss of 13%, normal hepatocyte at day 1 was maintained till day 3 p.i. After day 3 the number of normal cells further decreased on day 7 by approximately 8.5% before recovery in group IV. Whereas in group V, initial loss of 21% in normal hepatocytes at 24 hr was maintained till day 7, thereafter, recovery was noted as evident

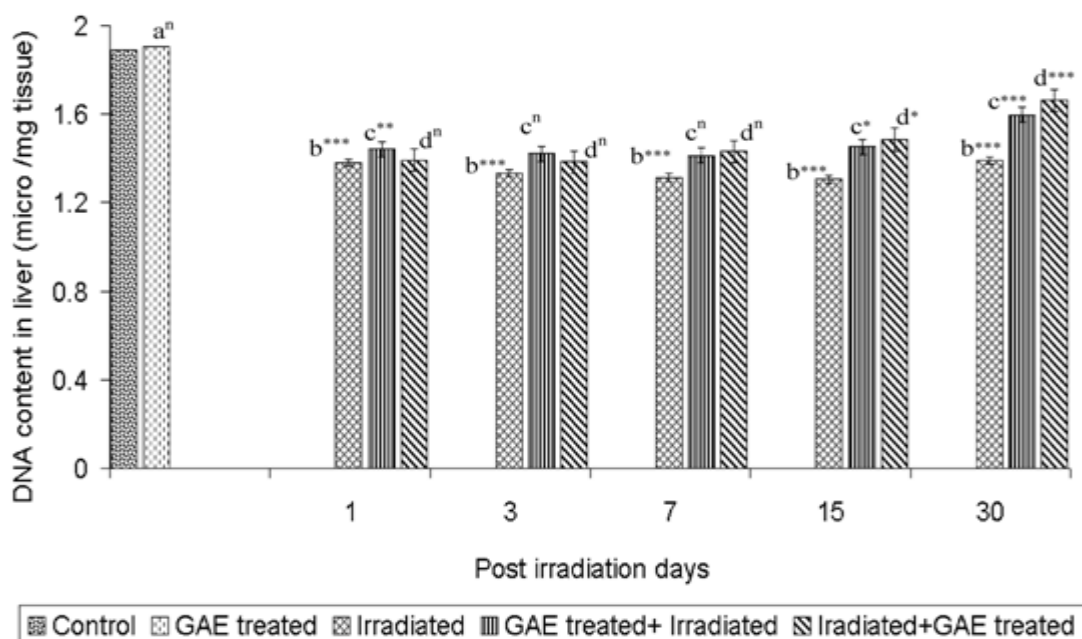


Figure 1. Graph showing variations in DNA content measured as $\mu\text{g/gm}$ tissue of mice liver in pre and post GAE (methanolic extract of *Grewia asiatica* fruit, 700mg/kg b.wt/day for 15 days) treated- irradiated group and irradiated group in comparison to control group and only GAE treated group. Data have been expressed as mean \pm SEM. P values of t-test n= non-significant, $* < 0.05$, $** < 0.01$, $*** < 0.005$, $**** < 0.001$; a: Control v/s GAE treated, b: Control v/s Irradiated, c: Irradiated vs GAE treated + Irradiated, d: Irradiated vs Irradiated + GAE treated.

by increase in number of normal cell till last autopsy interval studied. Administration of GAE prior to irradiation maintained a higher percentage of normal hepatocytes in comparison to irradiated group as well as IR+GAE treated group (figure 2). Supplementation of GAE for 15 days did not induce any significant change in percentage of normal hepatocytes in only GAE treated group. One-way ANOVA comparison between four groups i.e. control, IR, GAE + IR and IR + GAE group, at each autopsy intervals showed highly significant differences in normal hepatocyte count in liver on day 1 ($F_{3,20}=610.9$, $p<0.0001$), day 3 ($F_{3,20}=641.6$, $p<0.0001$), day 7 ($F_{3,20}=789.8$, $p<0.0001$), day 15 ($F_{3,20}=419.0$, $p<0.0001$) and day 30 ($F_{3,20}=239.3$, $p<0.0001$) p.i. respectively.

Irradiation caused biphasic increase in percentage of binucleate hepatocytes in our study. First peak was noted at day 1 followed by decrease at day 3 p.i. Second peak was noted on day 7, which continued upto the last interval studied (figure 3). In GAE+IR group, the percentage counts of

binucleated hepatocytes were increased till day 7 p.i. with slight decline on day 3, thereafter it decreased till last autopsy interval, but failed to attain the normal value of control group. However, population of these cells was considerably low ($p<0.001$) as compared to corresponding irradiated group at all the autopsy intervals. In IR+GAE group, the percentage counts of binucleated hepatocytes increased continuously till day 7 p.i., thereafter it decreased till last autopsy interval, but failed to attain the control value. The number of cells were significantly higher till day 7, there after the number significantly ($p<0.001$) decreased till last autopsy interval than there corresponding irradiated group (figure 4). Only GAE treated group showed significant ($p<0.005$) deficit in percentage counts of binucleated hepatocytes. One-way ANOVA comparison between four groups i.e. control, IR, GAE + IR and IR + GAE group, at each autopsy intervals showed highly significant differences in binucleated hepatocyte count in liver on day 1 ($F_{3,20}=85.99$, $p<0.0001$), day 3 ($F_{3,20}=730.5$, $p<0.0001$), day 7 ($F_{3,20}=212.6$,

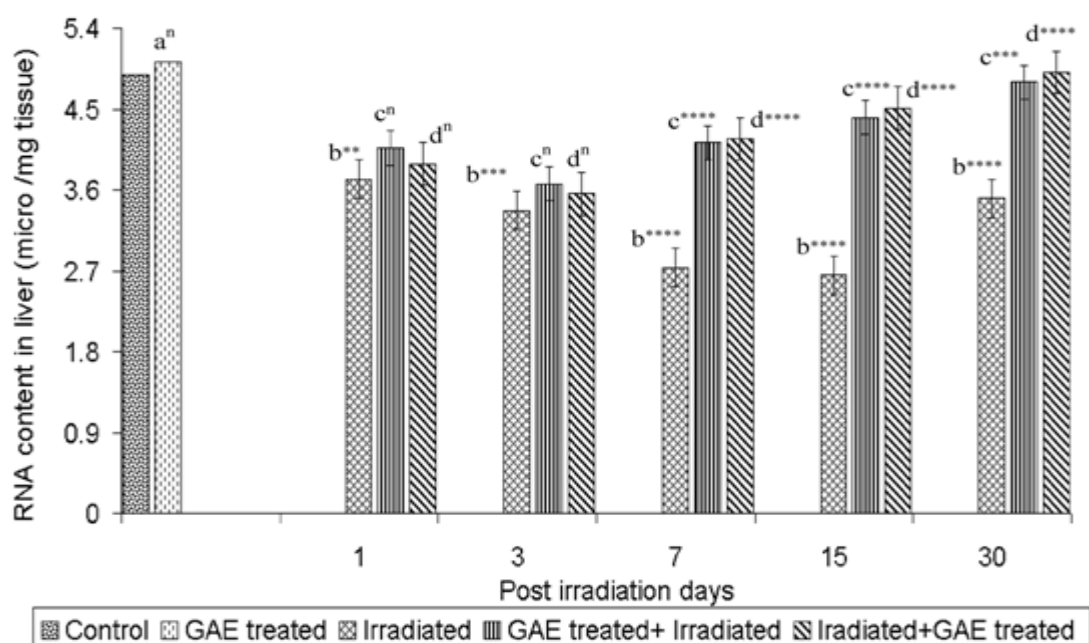


Figure 2. Graph showing variations in RNA content measured as $\mu\text{g}/\text{gm}$ tissue of mice liver in pre and post GAE (methanolic extract of *Grewia asiatica* fruit, 700mg/kg b.wt/day for 15 days) treated- irradiated group and irradiated group in comparison to control group and only GAE treated group. Data have been expressed as mean \pm SEM. P values of t-test n= non-significant, * <0.05 , ** <0.01 , *** <0.005 , **** <0.001 ; a: Control v/s GAE treated, b: Control v/s Irradiated, c: Irradiated vs GAE treated + Irradiated, d: Irradiated vs Irradiated + GAE treated.

p<0.0001), day 15 ($F_{3,20}=562.4$, p<0.0001) and day 30 ($F_{3,20}=815.6$, p<0.0001) p.i. respectively.

Statistically significant (p<0.001) increased in abnormal cells was noted at all autopsy intervals in group III. The initial

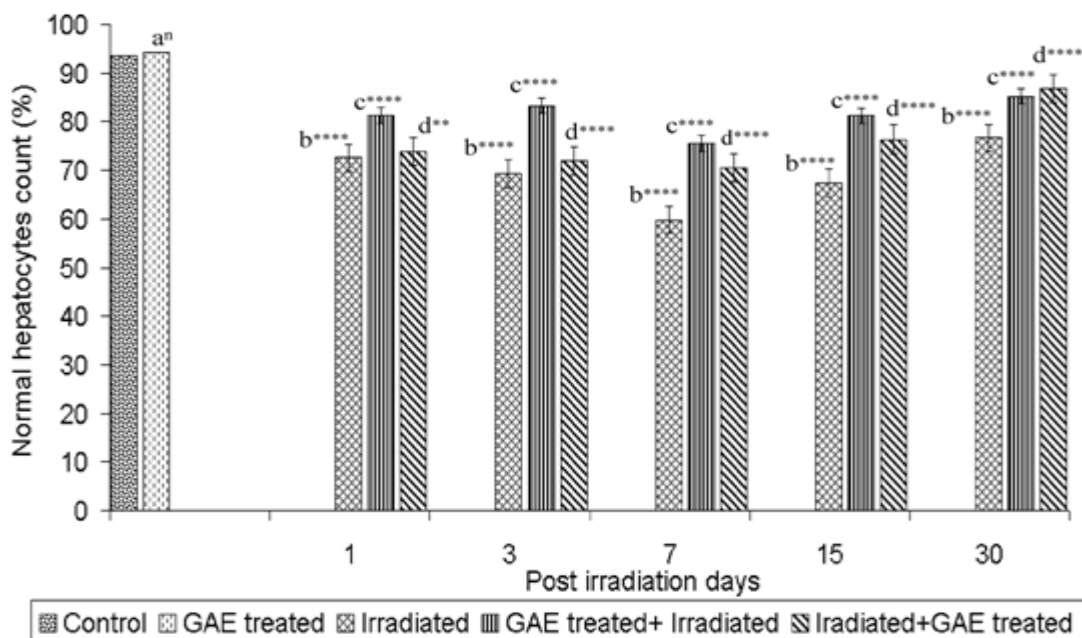


Figure 3. Graph showing variations in Normal hepatocyte count (%) of mice liver in pre and post GAE (methanolic extract of *Grewia asiatica* fruit, 700mg/kg b.wt/day for 15 days) treated- irradiated group and irradiated group in comparison to control group and only GAE treated group. Data have been expressed as mean \pm SEM. P values of t-test n= non-significant, *<0.05, **<0.01, ***<0.005, ****<0.001; a: Control v/s GAE treated, b: Control v/s Irradiated, c: Irradiated vs GAE treated + Irradiated, d: Irradiated vs Irradiated + GAE treated.

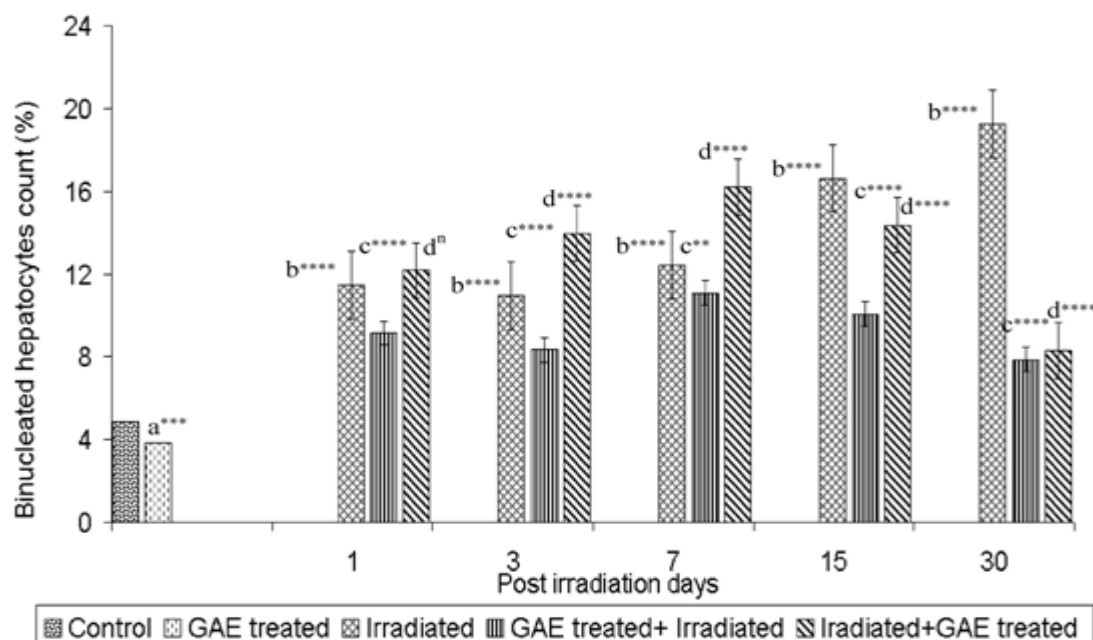


Figure 4. Graph showing variations in Binucleated hepatocytes count (%) of mice liver in pre and post GAE (methanolic extract of *Grewia asiatica* fruit, 700mg/kg b.wt/day for 15 days) treated- irradiated group and irradiated group in comparison to control group and only GAE treated group. Data have been expressed as mean \pm SEM. P values of t-test n= non-significant, *<0.05, **<0.01, ***<0.005, ****<0.001; a: Control v/s GAE treated, b: Control v/s Irradiated, c: Irradiated vs GAE treated + Irradiated, d: Irradiated vs Irradiated + GAE treated.

increase in abnormal cell count continued upto 7 day *p.i.*, where the increase was approximately 18 times than the control cell count. Thereafter abnormal hepatocytes count started to decrease and at day30, abnormal cell count was still 5.5 times higher than control level. Supplementation of GAE (prior/post) drastically reduced the number of abnormal cells. In the GAE+IR group, the percentage of abnormal hepatocytes count was considerably less (approximately 50%) as compared to corresponding control level at each autopsy interval (figure 5). Only GAE treated group showed significant ($p < 0.05$) decreased in percentage counts of abnormal hepatocytes. One-way ANOVA comparison between four groups i.e. control, IR, GAE + IR and IR + GAE group, at each autopsy intervals showed highly significant differences in abnormal hepatocyte count in liver on day 1 ($F_{3,20}=1235.0$, $p < 0.0001$), day 3 ($F_{3,20}=531.8$, $p < 0.0001$), day 7 ($F_{3,20}=661.7$, $p < 0.0001$), day 15 ($F_{3,20}=2027.0$, $p < 0.0001$) and day 30 ($F_{3,20}=481.3$, $p < 0.0001$) *p.i.* respectively.

DISCUSSION

In the present study, photomicrograph showed that irradiation caused radiolesions in various form in liver. Several workers have reported similar histopathological lesions in liver after internal or external radiation treatment⁽²³⁾. This also supported by change in the different hepatocytes count as well as DNA and RNA content in liver. Mansour *et al.*⁽²⁴⁾ also reported that liver of rat treated with 6 Gy γ -radiations displayed fragmentation of the hepatic cells in addition to the presence many of the hepatocytes manifested pyknotic nuclei and also many of aggregated inflammatory cells were detected. Radiolesions in the form of vacuolation in cytoplasm, dislocation of nuclei, enucleated cells, pyknotic nuclei, hyperaemia, haemorrhage and lymphocytic infiltration have been described following internal irradiation and external irradiation⁽²⁵⁾. Disturbed cellular metabolism related to protein fat and enzymes might be responsible to produce cloudy swelling, degeneration

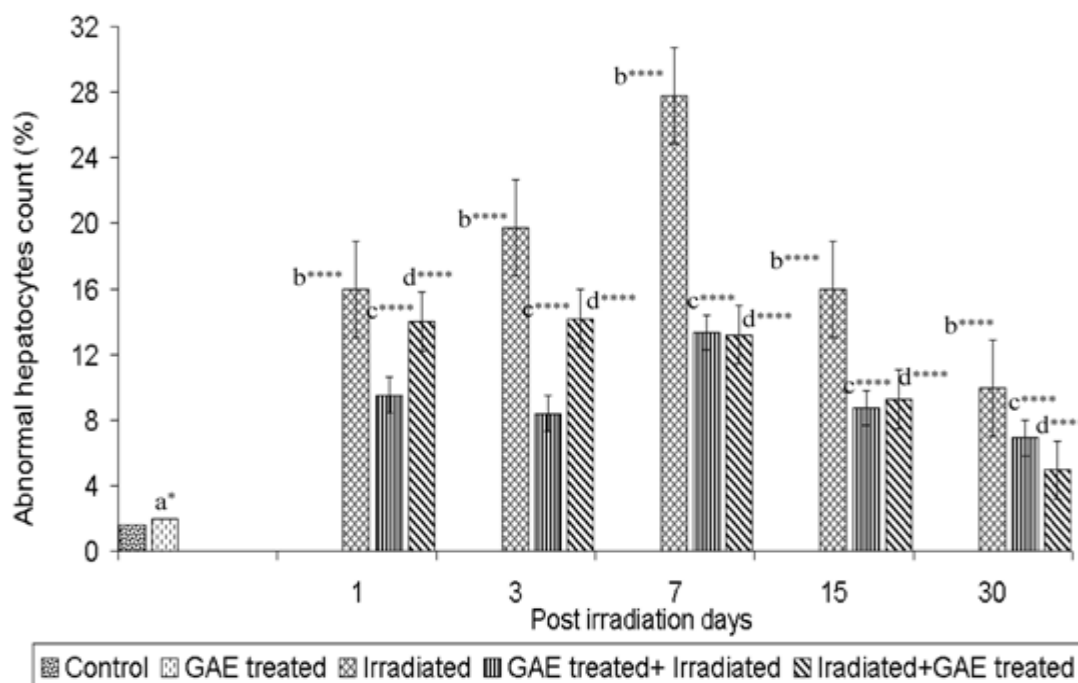


Figure 5. Graph showing variations in Abnormal hepatocyte count (%) of mice liver in pre and post GAE (methanolic extract of *Grewia asiatica* fruit, 700mg/kg b.wt/day for 15 days) treated- irradiated group and irradiated group in comparison to control group and only GAE treated group. Data have been expressed as mean \pm SEM. P values of t-test n= non-significant, * < 0.05 , ** < 0.01 , *** < 0.005 , **** < 0.001 ; a: Control v/s GAE treated, b: Control v/s Irradiated, c: Irradiated vs GAE treated + Irradiated, d: Irradiated vs Irradiated + GAE treated.

with small and large vacuoles in hepatocytes after irradiation in present study. Roudkenar *et al.* ⁽²⁶⁾ also showed a slight increase in the number and size of Kupffer's cell and dilation of sinusoids in comparison to non-irradiated control mice.

The histopathological observation revealed that the reason for an early increase of the binucleate cells before degeneration is due to the fusion of liver cells. Observation on the third day post-treatment exhibit that radiation caused the death and removal of binucleate cells which resulted in the depletion of such cells and some of these even form mononucleate giant cells. The second elevation in binucleated cells in irradiated group caused during the recovery period may be due to the failure of complete telophase separation of the post-mitotic cell or inhibition of cell division by radiation or lead induced G₂ block. Gajawat and Goyal ⁽²⁷⁾ also observed a biphasic pattern of radiation induced binucleated cell elevation in the mouse liver after gamma irradiation.

The histopathological alterations exhibited a correlation with the number of abnormal cells in the present study. The elevation in their number is associated with an increase in radiation induced lesions and these cells declined during the recovery phase. Similar observations were made by others ⁽²⁸⁾, who suggested that the percentage of dead and abnormal cells serve as good indicators of teratogenic sensitivity of liver cells.

Maharwal *et al.* ⁽²⁹⁾ found increased in percentage of binucleated and abnormal cell in mice liver by whole body exposure with 6, 8 and 10 Gy of gamma radiation at various post irradiation interval between 1 -30 days, they also found that the increase in the percentage of these hepatocytes was radiation dose-dependent in the irradiated mice. Similarly Sharma and Sharma ⁽²³⁾ found that number of binucleated cells and abnormal hepatocytes increased in mice liver after irradiation.

Binucleate and multinucleate giant cells might also be formed as a result of the failure of cell separation after completion of mitosis, or due to fusion of cells ⁽²³⁾. According to Gupta and Uma Devi ⁽³⁰⁾ giant cell formation is an irreversible phenomenon and it seems to be step before degeneration and cell death.

In present study, Nuclear changes appeared on day 7 (pyknosis, condensation of chromatin) which are considered as sign of "early necrosis". The number of pyknotic cells increased on day 7. The peroxidation of lipid portion of the membranes which was found to be elevated on day 7 ^(14, 15) appears to be responsible for pyknosis and other structural and functional changes in liver.

Among the cellular constituents, DNA is particularly sensitive to OH* radical-induced damage, which generates both DNA strand breakage and base hydroxylations resulting in generation of genetic alterations such as mutations or rearrangements ⁽³¹⁾. A highly significant (P < 0.001) decrease in liver DNA and RNA contents was observed in gamma-irradiation (6.0 Gy) compared with that of the normal rat group without irradiated ⁽³²⁾.

Reduced DNA and RNA noticed post-irradiation in present study also, which may be due to acute cell death leading to loss of DNA in excess than is normally eliminated from the tissue. The prolonged interphase or delayed onset of DNA synthesis after irradiation also could lead to decreased content of DNA. Egana *et al.* ⁽³³⁾ corroborated present finding that ⁶⁰Co gamma irradiation had more negative effect in DNA, RNA and protein function of liver. Studies ^(34, 35) show that anthocyanins can protect the DNA damage via protecting DNA from oxidation. One of possible mechanisms is that the anthocyanin forms the copigmentation with DNA, and further protects the DNA from the damage ⁽³⁴⁾. Galvano *et al.* ⁽³⁵⁾ also demonstrated that diet containing 100 mg/kg cyanidin-3-glycoside for 12 weeks could protect the

DNA single strand break induced by oxidative damage in vitamin E deficient rats. GAE pre and post-treated irradiated groups countered the radiation-induced decrease in DNA and RNA content reflecting preservation of genetic machinery. It was also proved that oral intake of anthocyanin increases total blood GSH and DNA fragmentation in mice and rats ⁽³⁷⁾.

Antonio *et al.* ⁽³⁸⁾ stated that carotenoids are 40 carbon molecules with conjugated double bonds, making them particularly effective for quenching free radicals. The presence of ascorbic acid and the flavonoids may be responsible for protection of DNA damage as these compounds are reported to protect the DNA from radiation-induced micronuclei in mice ⁽³⁹⁾.

Delgado Vargas *et al.* ⁽⁴⁰⁾ demonstrated that anthocyanins have scavenging properties against $\cdot\text{OH}$ and O_2 and are better agents against lipid peroxidation than α -tocopherol (up to seven times). Mechanisms of antioxidative action of vitamin C are direct scavenging and blocking of ROS, as well as regeneration of other antioxidative systems ⁽⁴¹⁾. Protective effects of vitamin C against ionizing radiation DNA damage have also been extremely documented ⁽⁴²⁾.

Sharma and Sisodia ⁽¹⁸⁾ also proved that GAE has the free radical scavenging activity by the DPPH* scavenging assessment ($\text{IC}_{50} = 218.47$ mg/ml) as well as the superoxide radicals generated from xanthine/xanthine oxidase assay were examined for the scavenging by the GAE extracts in comparison with cytochrome C ($\text{IC}_{50} = 15.18$ mg/ml). They also showed that GAE inhibits the protein carbonylation formation in BSA in *in vitro* study ($\text{IC}_{50} = 26.66$ mg/ml for GAE)

The exact mechanism by which GAE protects against radiation-induced damage is not fully understood. But as Sharma and Sisodia ⁽¹⁸⁾ demonstrated that the GAE has a strong radical scavenging activity in DPPH* and O_2^- assays in a concentration

dependent manner and *in vitro* radioprotective activity in protein carbonyl estimation assay suggests that the radioprotective potential of GAE may be due to free radical scavenging power by the antioxidant present in it like anthocyanin Vit. C and carotenes.

This suggests that *Grewia asiatica* fruit extract (Phalsa) could be a potential candidate for screening as a radioprotector for clinical applications.

ACKNOWLEDGMENT

Authors gratefully acknowledge Dr. A.A. Chogule, and the Department of Radiobiology, SMS Medical College and Hospital, Jaipur, India, for the irradiation facilities and dosimetry. No financial grant received.

REFERENCES

- Karran P (2000) DNA double strand break repair in mammalian cell. *Curr Opin Genet Dev*, **10**: 144–150.
- Gracy RW, Talent JM, Kong Y, Conard CC (1999) Reactive oxygen species: the unavoidable environmental insults. *Mutat Res*, **428**: 17-22.
- Chittezhath M, Kuttan G (2006) Radioprotective activity of naturally occurring organosulfur compounds. *Tumori*, **92**: 163-169.
- Saint-George LD (2004) Low-dose ionizing radiation exposure: Understanding the risk for cellular transformation. *J Biological Regulators and Homeostatic Agents*, 96-100.
- Haydont V, Bourgier C, Vozenin-Brottons MC (2007) Rho/ROCK pathway as a molecular target for modulation of intestinal radiation-induced toxicity. *British Journal of Radiology*, **80**: S32-S40.
- Weiss JF and Landauer MR (2003) Protection against ionizing radiation by antioxidant nutrients and phytochemicals. *Toxicology*, **189**: 1-20.
- Hays WB (1953) Fruit growing in India. 2nd Revised edition. Kitabistan, Allahabad, India.
- Sastri BN (1956) The wealth of India: Raw materials#4. *Grewia linn. Tilliaceae*. In: New Delhi, India, Council of Scientific and Industrial Research, 260-266.
- Morton JF (1987) Phalsa, fruits of warm climate, Miami: Julia Morton, 276–77.
- Yadav AK (1999) Phalsa: A Potential New Small Fruit for Georgia. *J Anick*, **45**: 348-352.
- Ahaskar M, Sharma KV, Singh S, Sisodia R (2007) Post treatment effect of *Grewia asiatica* against Radiation Induced Biochemical Changes in brain of Swiss Albino Mice. *Iranian Journal of Radiation Research*, **5**: 105-112.
- Sisodia R, Ahaskar M, Sharma KV, Singh S (2008) Modulation of radiation induced biochemical changes in

- cerebrum of Swiss albino mice by *Grewia asiatica*. *Acta Neurobiologiae Experimentalis*, **68**: 32-38.
13. Ahaskar M, Sharma KV, Singh S, Sisodia R (2007) Post treatment effect of *Grewia asiatica* against Radiation Induced Biochemical Changes in cerebrum of Swiss Albino Mice. *Pharmacologyonline*, **2**: 344-354.
 14. Sharma KV, Ahaskar A, Singh S, Sisodia R (2007) Modulation of radiation induced biochemical alteration in Swiss albino mice by *Grewia asiatica* (phalsa). *Pharmacologyonline*, **1**: 46-54.
 15. Sisodia R, Singh S, Sharma KV, Ahaskar M (2008) Post treatment effect of *Grewia asiatica* against radiation induced biochemical alterations in Swiss albino mice. *Journal of Environmental Pathology, Toxicology and Oncology*, **27**: 113-121.
 16. Singh S, Sharma KV, Ahaskar M, Sisodia R (2008) Protective role of *Grewia asiatica* on blood after radiation exposure in mice. *Journal of Complementary and Integrative Medicine*, **5(1)**: article 14.
 17. Ahaskar M, Sharma KV, Singh S, Sisodia R (2007) Radioprotective effect of the fruit extract of *Grewia asiatica* in Swiss albino mice against lethal dose of γ -irradiation. *Asian J Exp Sci*, **21**: 295-308.
 18. Sharma KV and Sisodia R (2009) Evaluation of free radical scavenging activity and radioprotective efficacy of *Grewia asiatica* fruit. *J Radio Prot*, **29**: 429-443.
 19. Sisodia R, Sharma KV, Singh S (2009) Acute toxicity effects of *Prunus avium* fruit extract and selection of optimum dose against radiation exposure. *Journal of Environmental Pathology, Toxicology and Oncology*, **28**: 303-09.
 20. Ceriotti G (1952) A microchemical determination of desoxyribonucleic acid. *J Biol Chem*, **198**: 297-303.
 21. Ceriotti G (1955) Determination of nucleic acids in animal tissue. *J Biol Chem*, **214**: 59-70.
 22. Mallory FB (1944) In: Humason GL, Freeman WH, editors. *Animal Tissue Techniques*. San Francisco, 150.
 23. Sharma R and Sharma J (2005) Modification of Gamma Ray induced changes in the mouse Hepatocytes by *Centella asiatica* extract: *In-vivo* studies. *Phytother Res*, **19**: 605-611.
 24. Mansour HH, Hafez HF, Fahmy NM, Hanafi N (2008) Protective effect of N-acetylcysteine against radiation induced DNA damage and hepatic toxicity in rat. *Biochemical Pharmacology*, **75**: 773-780.
 25. Mehata S, Mehata L, Mongia SP (1975) Effect of whole body X-irradiation on liver of Swiss albino mice. *Int J Exp Biol*, **13**: 73-75.
 26. Roudkenar MH, Li L, Baba T, Kuwahara Y, Nakagawa H, Wang L, Kasaoka S, Ohkubo Y, Ono K, Fukumoto M (2008) Gene expression profiles in mouse liver cells after exposure to different types of radiation. *J Radiat Res*, **49**: 29-40.
 27. Gajawat S and Goyal PK (2003) Prophylactic role of vit E against radiation induced biochemical alteration in the liver of Swiss albino mice. *Proc Nat Acad Sci India*, **73**: 269-274.
 28. Gajawat S, Sancheti G, Goyal PK (2005) Vitamin C against concomitant exposure to heavy metal and radiation: A study on variations in hepatic cellular counts. *Asian J Exp Sci*, **19**: 53-58.
 29. Maharwal J, Samarth RM, Saini MR (2005) Antioxidative effect of Rajgira leaf extract in liver of Swiss albino mice after exposure to different doses of gamma radiation. *Phytother Res*, **19**: 717-20.
 30. Gupta ML and Uma devi P (1981) Formation of giant hepatocytes in response to radiation. *Curr Sci*, **50**: 637-638.
 31. Wiseman H and Halliwell B (1996) Damage to DNA by reactive oxygen and nitrogen species: Role in inflammatory disease and progression to cancer. *Biochemical Journal*, **313**: 17-29.
 32. Abou-Seif MA, El-Naggar MM, El-Far M, Ramadan M, Salah N (2003). Amelioration of radiation-induced oxidative stress and biochemical alteration by SOD model compounds in pre-treated γ -irradiated rats. *Clinica Chimica Acta*, **337**: 23-33.
 33. Egana E, Liona I, Raimirej MT (1983) Effect of whole body gamma radiation in DNA, RNA and protein function in developing CNS. In: *Proc. VII Int Cong Radiat Res*, p. 1-7.
 34. Duthie SJ, Gardner PT, Morrice PC, Wood SG, Pirie L, Bestwick CC, Milne L, Duthie GG (2005) DNA stability and lipid peroxidation in vitamin E-deficient rats *in-vivo* and colon cells *in-vitro* modulation by the dietary anthocyanin, cyanidin-3-glycoside. *Eur J Nutr*, **44**: 195-203.
 35. Kong JM, Chia LS, Goh NK, Chia TF, Brouillard R (2003) Analysis and biological activities of anthocyanins. *Phytochemistry*, **64**: 923-933.
 36. Galvano F, La Fauci L, Lazzarino G, Fogliano V, Ritieni A, Ciappellano S, Battistini NC, Tavazzi B, Galvano G (2004) Cyanidins: metabolism and biological properties. *J Nutr Biochem*, **15**: 2-11.
 37. Weisl T, Baum M, Eisenbrand G, Dietrich H, Will F, Stockis JP, Kulling S, Rufer C, Johannes C, Janzowski C (2006) An anthocyanin/polyphenolic rich fruit juice reduce stress DNA damage and increase glutathione level in healthy probands. *J Biotechnol*, **1**: 388-397.
 38. Antonio CJ, Asad LM, Oliveira EB, Kovary K, Asad NR, Felzenszwalb I (2005) Antigenotoxic and antimutagenic potential of an annatto pigment (norbixin) against oxidative stress. *Genet Mol Res*, **4**: 94-99.
 39. Jagetia GC and Reddy TK (2002) The grapefruit flavanone naringin protects against the radiation-induced genomic instability in the mice bone marrow: a micronucleus study. *Mutation Research/Genetic Toxicology and Environmental Mutagenesis*, **519**: 37-48.
 40. Delgado-Vargas F, Jimenez AR, Paredes-Lopez O (2000) Natural pigments: carotenoids, anthocyanins, and betalains-characteristics, biosynthesis, processing, and stability. *Food Science and Nutrition*, **40**: 173- 289.
 41. Griffi HR and Lunec J (2001) Ascorbic acid in the 21st century: more than a simple antioxidant. *Environ Toxicol Pharmacol*, **10**: 173-82.
 42. Konopacka M, Widel M, Rzeszowska-Wolny M (1998) Modifying effect of vitamins C, E and beta-carotene against gamma-ray-induced DNA damage in mouse cells. *Mutat Res*, **417**: 85-94.

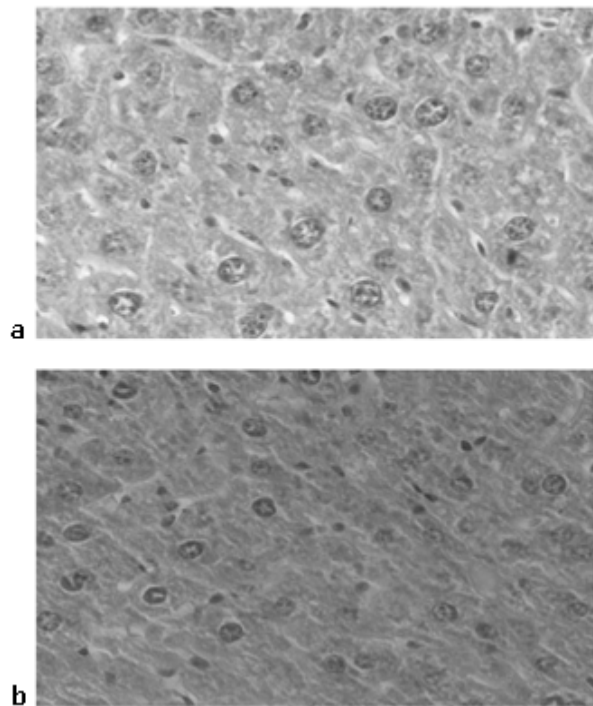


Plate 1. Photomicrograph of normal hepatocytes in T.S. of liver of control mice (a) as well as in liver of only GAE treated group (b) at 400X.

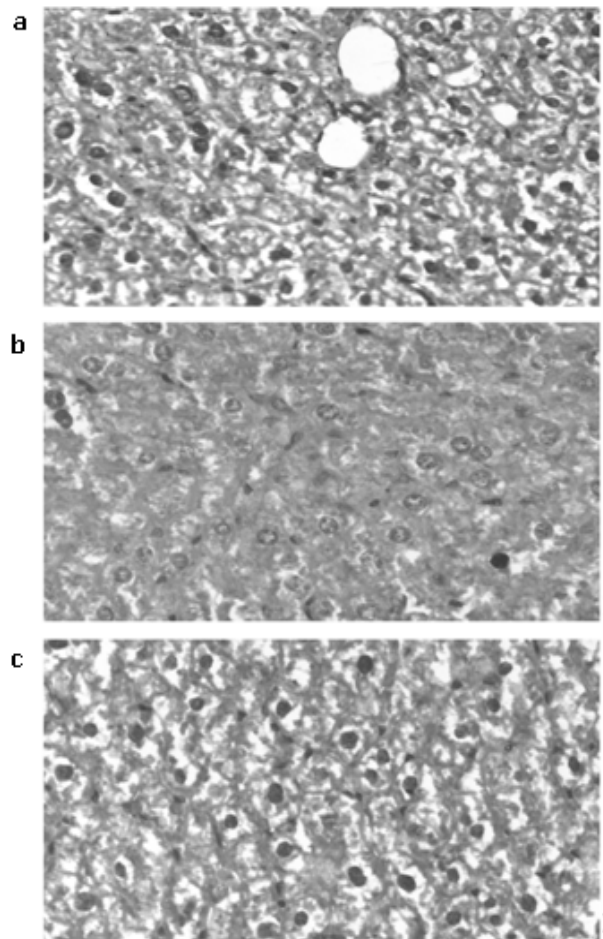


Plate 2. Photomicrograph of T.S. of liver at day 7 post irradiation of Irradiated group (a) and Irradiated + GAE treated group (c), showing the completely distorted hepatic architecture, wider sinusoids, sever cytoplasmic vaculation and pycnotic nuclei along with elongated nuclei whereas photomicrograph of GAE treated + Irradiated group (b) showed the slightly distorted hepatic arrangement, less wider sinusoidal space, lymphatic infiltration and binucleated hepatocytes at 400X.

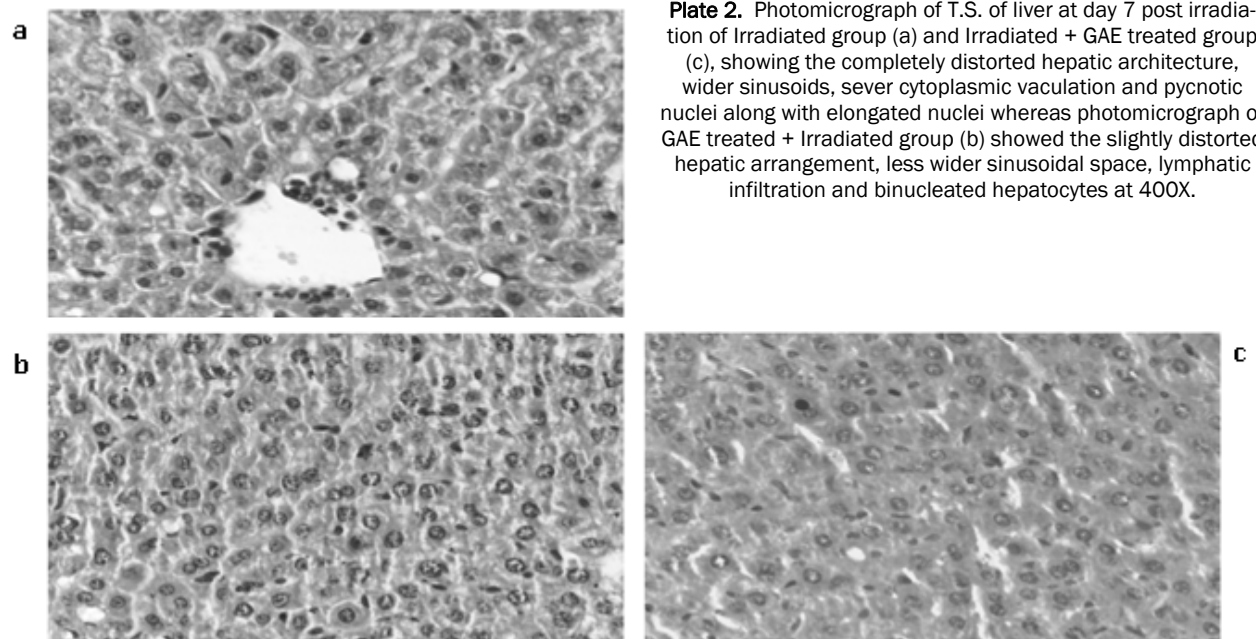


Plate 3. Photomicrograph of T.S. of liver at day 30 post irradiation of Irradiated group (a) showing slight recovery with crenated nuclei and giant hepatocytes, but photomicrograph of GAE treated + Irradiated group (b) showed the arranged hepatic architecture, dissociation of giant hepatocytes with parenchymatous islands whereas photomicrograph of Irradiated + GAE treated group (c), also showing the recovery in the hepatocytes architecture at 400X.

