

MRI evaluation of rabbit bone marrow after acute irradiation

Sh. Akhlaghpoor^{1,2*}, H. Khani¹, F. Kossari², M. H. Zahmatkesh¹

¹ Novin Medical Radiation Institute, Tehran, Iran

² Tehran University of Medical Sciences, Tehran, Iran

ABSTRACT

Background: Magnetic Resonance Imaging (MRI) is a safe modality and useful in characterizing normal and abnormal bone marrow (BM). MRI also presents a more global view of BM than biopsy; therefore, it may provide a better understanding of hematologic disorders. The purpose of this study was to monitor radiation-induced alterations of BM in acute phase of irradiation (1-10 day after total body irradiation (TBI)) with conventional MRI.

Materials and Methods: Twelve New Zealand adult male white rabbits (10 for TBI and 2 as controls) were irradiated to 6 Gy gamma rays. MRI was performed for each rabbit femoral marrow and marginal muscles around femur region (as internal control) using T1- weighted (W) and SPIR (TR/TE 631/15) techniques before and after (24h, 48h, 72h, 5d, 10d) post TBI.

Results: The results were expressed as MR signal ratio (mean MR signal of femur/mean MR signal of muscle). The BM MR –signal intensity (SI) values were subsequently compared to the histologic values of BM cellularity, edema and hemorrhage. Values of T1-SI of BM for 1 to 5 days after irradiation was smaller than those the values for before irradiation data ($P < 0.006$). SPIR-SI values of BM in 3, 5 and 10 days were less than values for before irradiation ($P < 0.001$). Since SI depends to edema and hemorrhage the high correlation between cellularity and T1-SI ($r = 0.725$, $P = 0.018$) or SPIR-SI ($r = 0.814$, $P = 0.004$) was not found.

Conclusion: This study indicated that radiation-induced modification of BM-SI is tightly linked to the parameters like decline of all hematopoietic cell lines, edema and hemorrhage. It was concluded that MRI can distinguish normal from irradiated BM so that radiation-induced alterations in BM could be assessed with MRI. *Iran. J. Radiat. Res., 2004; 2 (3): 117-126*

Keywords: Acute irradiation, BM cellularity, BM edema & hemorrhage, MR -SI.

INTRODUCTION

Evaluation of the hematopoietic BM is achieved by various methods such as conventional radiography, scintigraphy, computed tomography (CT), needle biopsy and MRI. These methods differ in sensitivity, specificity and accuracy (Volger 1998), and, each is well suitable enough to evaluate specific disorders. However, needle biopsy and MRI are considered as the best techniques for detailed inves-

tigation of the hematopoietic BM (Casamassima *et al.* 1989). BM contains a large portion of mobile protons in fat and water in hematopoietic cells and stromal tissue. It is therefore ideally suited to be studied by MRI (Vogler 1998, Cavenagh *et al.* 1995, Steiner *et al.* 1990, 1993).

Although needle biopsy is more specific than MRI (however with same sensitivity) and enables accurate characterization of tissue histology, it is an invasive technique that involves notable risk and patient discomfort. Furthermore, biopsy technique in a single site does not allow the study of large volumes of marrow and may not always be representative of entire hematopoietic BM.

MRI on the other hand, enables direct

*** Corresponding author:**

Dr. Sh. Akhlaghpoor, Novin Medical Radiation Institute,

P.O.Box: 14665-599, Tehran, Iran.

Fax: +98 21 8086782

E-mail: shahram_ak@yahoo.com

evaluation of large portions of BM, providing detailed insight into its distribution and viability. It is also useful in the early diagnosis of lymphomas, leukemia, metastases and primary bone tumors, as well as in the follow up of patients treated with radiation therapy (RT) or chemotherapy. From a practical standpoint, it is a non-invasive technique and can be safely repeated without any risk or discomfort for the patient. A known disadvantage of MRI in compare to needle biopsy is its lower specificity (Casamassima *et al.* 1989).

The hematopoietically active BM represents the most appropriate model to study radiation-induced injuries. MRI can clearly detect the depletion of myeloid elements and the increase of adipocyte that occur as a consequence of RT (Vogler 1998, Ramsey *et al.* 1985, Remedios *et al.* 1988, Yankelevitz *et al.* 1991, Kauczor *et al.* 1993). The alterations of the MR signal closely correlate with radiation-induced alteration of the hematopoietic marrow that has been determined by invasive techniques. The pattern of myeloid depletion and fatty substitution is in turn indicative of the extent of tissue damage (Casamassima *et al.* 1989). In this study we have evaluated the early changes in MR Signal Intensity (SI) of BM after acute single dose irradiation with histopathological correlation.

MATERIALS AND METHODS

Animals

Sixteen healthy New Zealand male adult white rabbits (Purchased from Razi institute, Karaj) aged between 3.5–4 months weighed 2.3 to 2.9 kg were used. They were kept in the institute's animal house for one week before beginning the experiments.

Imaging

All animals were imaged before and after irradiation using a 0.5T PHILIPS MRI (GYROSCAN). The rabbits were put in a cardboard cage and the assembly of cage and rabbit were fixed in the neck coil while imaging. T1-W and SPIR (TR/TE, 631/15) were used as two imaging techniques. For each rabbit an image that femur was shown in a longitudinal, T1 and SPIR axial images were designed and performed. Osiris software was used for reviewing of the images. With this software proper profiles of images were selected and magnified and a region of interest (ROI) was constructed to record the SI (figure 1). The SI for all profiles were measured and recorded. SI for muscle were also calculated and recorded separately.

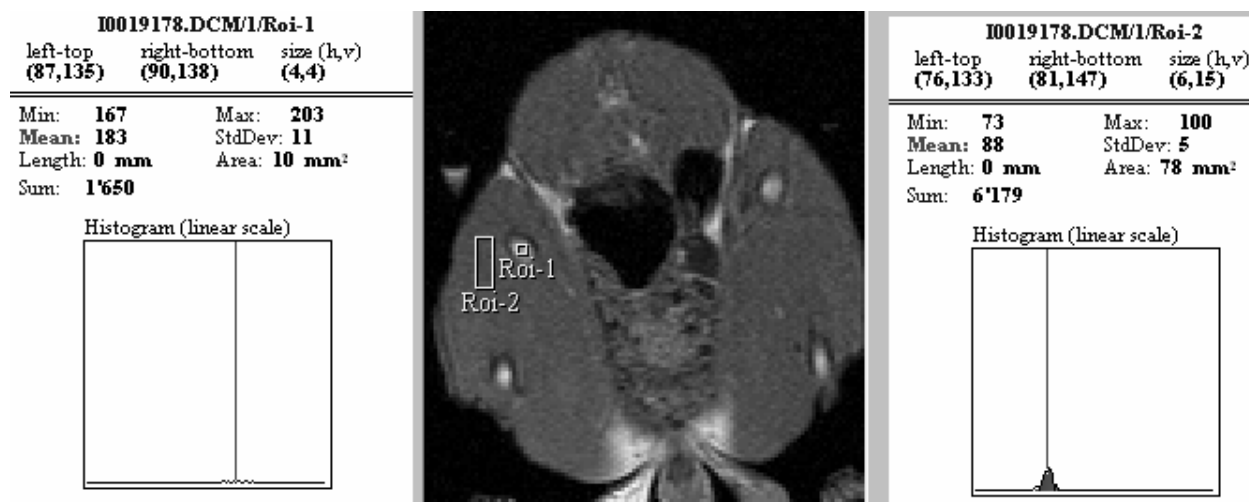

Figure 1. Method of computing the MR Signal ratio (Normal MR signal ratio=BM SI / Muscle SI). Giving in this example a MR signal ratio of 2.07.

Irradiation

All animals except the controls were irradiated to 6 Gy of gamma rays generated from a cobalt 60 unit (Thratron 780C) at a dose rate of 111.129 cGy/min.

Pathological studies

After irradiation, animals were scarified and their BM extracted. Smears from different parts of BM were provided and stained with hematoxylin eosin (H & E) Technique. Microscopic evaluation was performed to determine the cellularity of BM by counting the cells in different fields and counting the hemorrhage centers produced in different fields. Photomicrographs of a normal and irradiated BM is shown in figure 2.

Statistical analysis

Mean SI of the whole femur in each image was determined using SPSS-10 software. Mean SI was also measured for muscle in the margin of femur as internal control for all slices. In each slice the ratio of SI of BM to muscle was calculated and was recorded as normalized signal of BM. Kolmogorov-Smirnov test was used for determining the situation of data distribution. for different times. The significance of signal variations for all imaging times and signals intensities of T1-W and SPIR were tested with Mann-Whitney U-test.

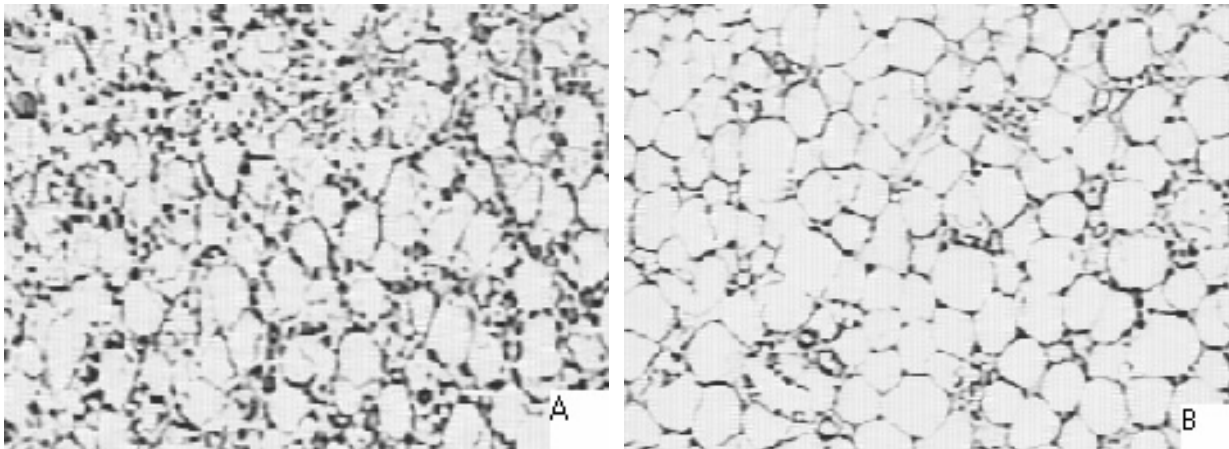


Figure 2. Microscopic view of Rabbit Bone marrow cells with 10 time magnification indicates reduced hematopoietic cells without any change in fat cells. A) Normal bone marrow; B) 72 h after radiation.

RESULTS

T1-W signals

Mean and standard deviation of normalized T1-SI of rabbit's BM is shown in figure 3. Kolmogorov-Smirnov test was proved that T1-SI of BM is a normal distribution. Mann-Whitney test was proved that: T1-W-SI variation between 0 and 1 or 2 days is significant ($p < 0.001$); T1-W-SI variation between 0 and 5 days is significant ($p = 0.006$); T1-W-SI variation between 0 and 10 days is insignificant ($p = 0.083$).

SPIR Signals

Normalized SPIR SI obtained from rabbit's BM for different times after irradiation is shown in figure 4.

Kolmogorov-Smirnov's test was shown that SPIR-SI for BM has a normal distribution. Mann-Whitney test showed that variations of SPIR-SI between 0 and 1, 2 days were not significantly different ($p > 0.239$); but variations of SPIR Signal between 0 and 3, 5, 10 days were significant ($p < 0.001$).

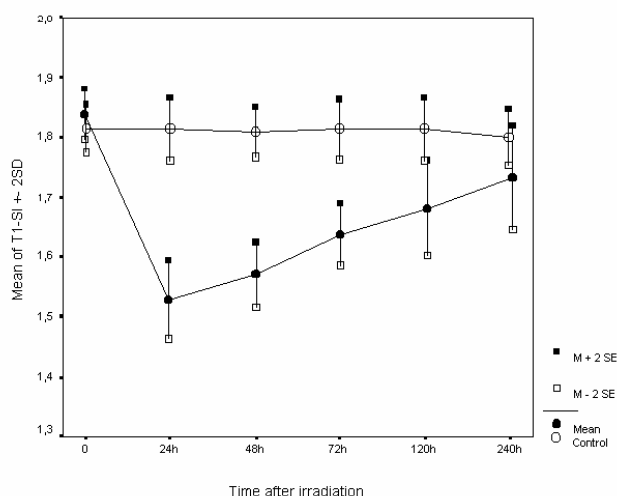


Figure 3. variations of mean normalized T1-W- BM -SI for control and irradiated rabbits to 6 Gy for different times after irradiation.

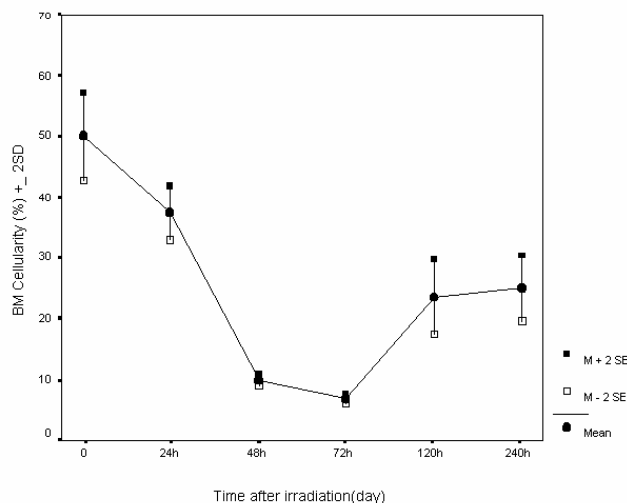


Figure 5. Variation of rabbit's BM cellularity after 6 Gy irradiation.

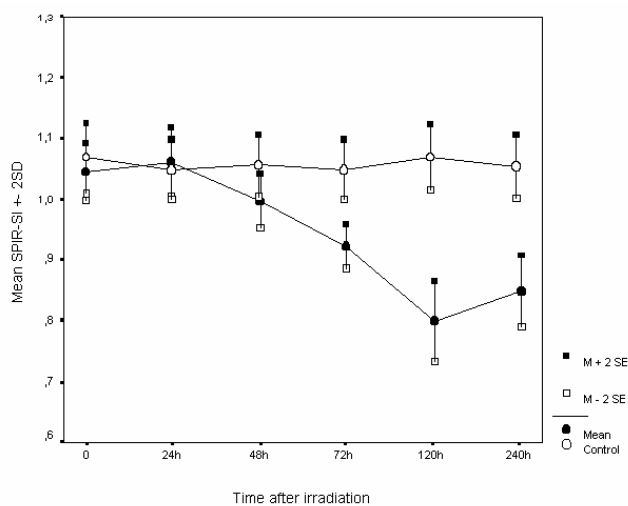


Figure 4. Variations of mean normalized SPIR BM -SI for control and irradiated rabbit to 6 Gy for different times after irradiation.

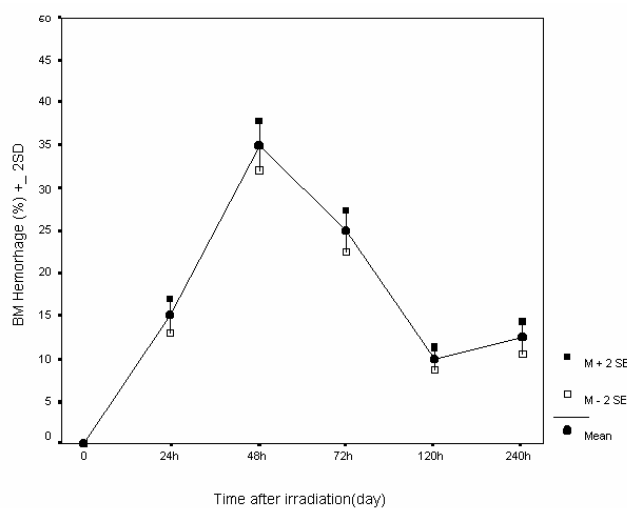


Figure 6. Variation of hemorrhage rate in BM in different times after irradiation.

BM Variation

BM cellularity variation due to irradiation is shown in figure 5. It was observed that number of femoral cells is reduced to 15% of the normal value after 72 hour post irradiation and then, it's recovery to normal situation was started so that, 10 days after irradiation femoral cell number increased to 35% of the normal value.

Hemorrhage in BM was investigated and its results are shown in figure 6.

Comparison of BM pathologic variation with MRI signal

Correlation rate between MRI signals and produced damaged due to gamma irradiation (6 Gy) in BM graphed as is shown in figures 7 and 8.

DISCUSSION

MR imaging is a non-invasive technique that a large volume of BM can be evaluated very easily. MRI can be considered as a compli-

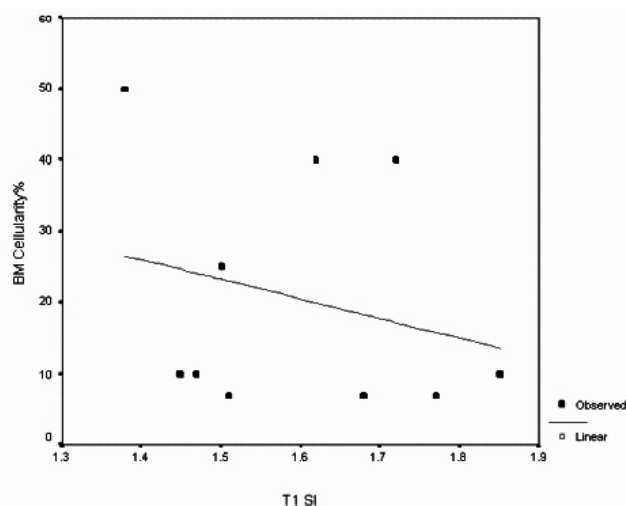


Figure 7. Regression graph of cellularity and T1-W-SI in rabbit's BM ($r = 0.725$, $p = 0.018$).

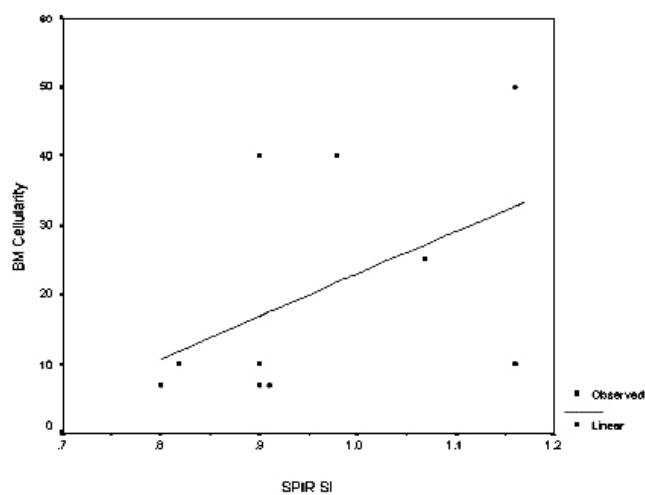


Figure 8. Regression graph of cellularity and SPIR -SI in rabbit's BM ($r = 0.814$, $p = 0.004$).

ment to BM biopsy and a procedure for treatment effectiveness, response to treatment (Lecouvet *et al.* 2001) in radiotherapy and chemotherapy (Pereira *et al.* 1999, Sacks *et al.* 1978, Parmentier *et al.* 1985).

Reciprocal relation between distribution rate of hematopoietic elements and fat tissue is a proved fact. Variation of hematopoietic and fat tissue is related to the age, however this variation also occurs in pathologic situation. Since MR-SI is related to hematopoietic elements and fat, change in the ratio of them can be observed

with MRI. MRI can also distinguish between variation of fat, fibrous, aplastic and hypercellularity. Therefore, using this procedure can results to useful information for diagnosis and follow up of hematopoietic related diseases.

Clinically, usually MR-SI is considered qualitative with reference to fat, muscle or CSF tissues (Volger *et al.* 1988, Cavenagh *et al.* 1995, Steiner *et al.* 1990, Rosen *et al.* 1988, Porter *et al.* 1986, Negendank *et al.* 1991, Linden 1989, Mouloupoulos *et al.* 1989,1992,1997, Vande *et al.* 1996).

It was always required to have a qualitative procedure to investigate the content of BM. With quantitative analysis of BM with the aid of MRI, a proper data of the BM content can be obtained (cellular BM and aplastic BM). Therefore, in this study, the variation of BM signals after irradiation was investigated quantitatively. Normally such studies are carried out in two ways:

In vivo measurement of T1 relaxation time or its value (Dooms *et al.* 1985) and *in vivo* proton spectroscopy (Casamassima *et al.* 1989, Remedios *et al.* 1998, Ricci *et al.* 1990, Gewirts 2003, ASGBS 1999, Ballon *et al.* 1991).

In this research, *in vivo* measurements of T1 and SPIR fat elimination are used.

MR signal in hematopoietic BM is related to proton density and relaxation time. In yellow BM and subcutaneous fat tissues, 100% of MR-SI is due to fats, but, hematopoietic BM is different from other tissues, because in normal people the ratio of water (in hematopoietic cells) and standard image (T1-W) is a result of two opposite signal from cellular and fat elements.

In these images high signal is produced due to increase of fat cell and low signal is due to reduction of fat cells, however factors such as trabecular bone tissue and myelofibrosis are effective and cause the reduction of BM signals (Mouloupoulos *et al.* 1997).

Total body irradiation (TBI) may happen due to accidents or due to treatment in radiotherapy. TBI can be a part of BM transplantation

(Mirowitz *et al.* 1994, Bydder and Young 1985). Active hematopoietic tissue is very sensitive to ionizing radiation. In the other side, red BM, which contains different levels of hematopoietic cells, and is an appropriate model to study radiation related damages to these cells.

BM-MR-SI is related to the presence of following elements: red bone marrow (hypercell), fatty BM (yellow) and calcified matrix.

In this study, acute dose (6 Gy) of gamma ray was used to investigate the damage due to acute irradiation in BM and its possible quick recovery to normal situation. This enables one to evaluate the variation of BM in short time after acute irradiation with MR imaging.

BM Variation

From pathology point of view, variations of peripheral blood and BM after irradiation have been studied extensively. The observed variation is in line with by other studies (Kaul *et al.* 1986). The pattern of the variations is approximately the same.

Variation of MR signals in BM

Investigations on BM- MR images of spinal cord after radiotherapy clearly showed the unusual increase of -SI in irradiated vertebra. This increase was due to fat increase in BM of that vertebra (Casamassima *et al.* 1989, Harris 1994, Yoffey and Parnell 1944, IAEA 1971, Stevens *et al.* 1990). This variation happen minimum 6 weeks and maximum 15 years post irradiation with doses in the rage of 8 to 60 Gy (Casamassima *et al.* 1989, IAEA 1971, Stevens *et al.* 1990, Dikovinova 1957, Sabin *et al.* 1936). Most studies with MR showed the continuity of MR-SI. This continuity was without any further change, which expresses the failure of BM recovery (Harris 1994, Yoffey and Parnell 1944, Dikovinova 1957, Sabin *et al.* 1936, Yam 1971). Shen *et al.* showed that, variation in BM signal will happen and it may continues for several years (Shen *et al.* 1990). Other researchers (Yankelevitz 1991, Starz *et*

al. 1990, Li *et al.* 1999) assigned the BM-SI variation after radiotherapy to replacement of fat in BM (Yankelevitz *et al.* 1991). Onu *et al.* (2001) observed the increase of T2 signal in BM after 15 days post irradiation with 9 Gy.

In a study carried on the patient treated with radiotherapy, it was shown that variation of BM after radiotherapy was observable in a premature condition after 8 days post irradiation (Blomlie *et al.* 1995). It was also shown (Casamassima *et al.* 1989) that produced variation on BM after irradiation can be evaluate with MRI and is related to two factors of delivered dose and elapsed time after irradiation. They proved that BM recovery is possible only for those treated with doses below 50 Gy.

This study also showed that rapid signs produced in BM to 6 Gy dose is the reason for variation in MR-SI in BM and this variation is detectable with MRI. Histopathology studies of BM showed that the reasons for signal variation are cellularity reduction, edema, hemorrhage, fat replacement, fibrous and regeneration of BM. As it was shown by previous researchers (Sugimura *et al.* 1994), variation of -SI in irradiated BM not only happens due to fat variation but also due to hemorrhage. In this method, MR images for before irradiation is needed to determine the produced variation after irradiation, but, because the signal variation is not detectable in first few hours after irradiation, therefore, MR imaging can be done in early hours of irradiation as a base line of imaging.

Kugel *et al.* (2001) showed that in age group less than 31 years, difference of BM signal for different people is maximum 12% and in ages between 31 to 50, this difference in BM-SI is higher but for older age groups this difference is very less. Therefore, with this categorization, a vast spectrum of ages can be investigated confidently.

Calculation of MR signal is very much dependant to the selection of control (Rozman *et al.* 1997), therefore, it's not easy to standardize it. Rozman *et al.* used spinal cord signal as a

control. In other studies (Iizuka *et al.* 2001), also spinal cord and muscle have been used as controls.

In this study in order to harmonize the condition, elimination of interfering parameters and standardizing MR signal, muscle was used as an internal control. Received signal from BM was evaluated in relation with signals from muscle in the margin of femur and its quotient was registered as normalized BM signal for both T1 and SPIR techniques.

T1- SI Variation

In this study, variation in BM was investigated with usual standard T1- W- SE technique. Figure 3 shows T1-W signal variation up to 10 days after irradiation. reduction of T1 signal in 24 and 48 h post irradiation are accomplished with severe reduction in cellularity and severe increase in hemorrhage (figures 5 and 6). This signal reduction is related to increase of blood plasma and reduction of hematopoietic cells of BM, which is agreement with previous studies (Sugimura *et al.* 1994).

In 72 h point after irradiation, signal reduction was continued but in compare to 24 and 48 h points, an increase in T1- SI was observed. But cellularity of BM is reduced and hemorrhage rate of BM was less in compare to previous day. We suggest that increase of signal in compare to 48-h point be related to the reduction of hemorrhage rate in compare to the day before and subsequently the reduction of incoming plasma to the BM space.

Sugimura *et al.* (1994) showed that in the critical phase of radiation (1-3 days), T1 time is longer which is the case in this study. As it was mentioned earlier, possibly this problem is due to cellularity reduction and edema. After this phase, shortening of T1 signals occurred which is related to hemorrhage. In the chronic phase up to day 10, recovery of BM was observed.

The mentioned results are in agreement with study by Tong *et al.* (1998). In that study rat had been irradiated to different doses and was

investigated with MRI. They showed that sinusoid expansion, hemorrhage, cellularity reduction 3 days after irradiation and fat replacement 12 days after irradiation in BM are observed. They also concluded that irradiation to a single dose causes obvious variation and rapid sequences of T1 and T2 in BM.

In day 5 after irradiation, T1 signal continued to increase. This increase was related to reduction of hemorrhage rate, edema and to some extent the recovery of BM. In day 10 after irradiation, T1 signal was closer to zero time signal and this occurred which BM cellularity also was increased and was close to normal value. The hemorrhage rate was also less and BM had recovered to a good extent. In overall it can be said that, BM signal reduction up to 24 and 48 h after irradiation is due to sinusoid vascular expansion, hemorrhage, edema and reduction of BM cellularity but from 48h time to day 10. increase of T1 signal is due to gradual reduction of edema, hemorrhage and relative compensation for BM cellularity. Therefore, the trend of T1 signal variation with pathological variation is related and is justified.

From statistical point of view, there was significant difference between T1- SI for zero time with 24 hour ($p<0.001$). Difference between signal intensities was also significant for times between zero and 5 days ($p<0.006$). But this variation was not significant in day 10 ($p=0.083$). Signal variation in 24 hours had its maximum peak that must be consider in clinical studies.

In previous studies, correlation between SI of BM and its cellularity was shown. In this study, correlations between T1-SI and BM cellularity are also studied. Results show that BM cellularity percentage with T1-SI have correlation ($r=0.725$, $p=0.018$).

$$\text{BM cellularity} = \text{T1-SI} * (-27.721) + 64.814$$

There was not a high correlation between hemorrhage and T1-SI ($r=0.237$, $p=483$). As it was mentioned earlier, in different studies, correlation between cellularity and BM- SI, was proved but in case of irradiation damage on

BM, because other parameters such as edema and hemorrhage are effective on MR signal, the correlation between cellularity and T1- SI was not observed.

SPIR-SI variation

As BM variation in acute irradiation is oriented towards hematopoietic cells and no sever change in BM fat deposition is occurred, therefore SPIR technique was applied to eliminate the SI in it's highest value to obtain signals purely due to variation of hematopoietic cells. In figure 4, variation of SPIR in animal BM is shown. This graph shows that SPIR signals after 24 hour has nearly increased and then due to severs reduction of BM cellularity, has started to decline. This reduction in day 5 reaches to its maximum value.

In this study, from correlation between BM signal and its cellularity view, SPIR signal and BM cellularity have been studied. Results shows that, BM cellularity percentage has correlation with SPIR- SI ($r = 0.814$, $p = 0.004$). There was not a good correlation between hemorrhage and SPIR signal ($r = 0.238$, $p = 481$).

BM cellularity = (SPIR- SI*61.325)-38.272

CONCLUSION

For investigation on irradiated patient and in radiation accidents, BM- MRI can be used as a noninvasive method. Correlation between BM cellularity and SPIR- SI is better than T1- W signal. There is no correlation between hemorrhage in BM, SPIR signals and BM T1- W.

One disadvantage of evaluation of irradiated individual with MRI is to require MR images for before irradiation to determine the variation. To overcome this disadvantage, MR imaging should be preformed in early hours of irradiation occurrence. It is necessary to use an internal control in order to produce a relative - SI. It is possible to apply MRI to evaluate the improvement of irradiated patient and review the recovery of BM. MRI is able to reveal the variation of BM content in 1-3 days after irradiation.

REFERENCES

- ASGSB (1999). Annual Meeting. Effect of radiation dose and dose rate on blood & spleen lymphocyte. At: www.asgsb.indstate.edu/programs/1999/105.html
- Ballon D., Jakubowski A., Gabrilove J., Graham M.C., Zakowski M., Sheridan C., Koutcher J.A. (1991). *In vivo* measurements of bone marrow cellularity using volume-localized proton NMR spectroscopy. *Magn. Reson. Med.*, **19**: 85-95.
- Blomlie V., Rofstad E.K., Skjonsberg A., Tvera K., Lien H.H. (1995). Female pelvic bone marrow: serial MR imaging before, during, and after radiation therapy. *Radiology*, **194**: 537-43.
- Bydder G.M. and Young I.R. (1985). NMR imaging: Clinical use of the inversion recovery sequence. *J. Comput. Assist. Tomogr.*, **9**: 659.
- Casamassima F., Ruggiero C., Caramella D., Tinacci E., Villari N., Ruggiero M. (1989). Hematopoietic bone marrow recovery after radiation therapy: MRI evaluation. *Blood*, **73**: 1677.
- Cavenagh E.C., Weinberger E., Shaw D.W.W., White K.S., Geyer J.R. (1995). Hematopoietic marrow regeneration in pediatric patients undergoing spinal irradiation: MR depiction. *AJNR*, **16**: 461-467.
- Dikovinova, N.V. (1957). The absolute number of cells in bone marrow and myelograms of normal rabbits. *Byull. Eksp. Biol. Med.*, **44**: 1129.
- Dooms G.C., Fisher M.R., Hricak H., Richardson M., Crooks L.E., Genant H.K. (1985). Bone marrow imaging: magnetic resonance studies related to age and sex. *Radiology*, **155**: 429-432.
- Gewirtz A.M. (2003). Effect of deep space radiation on human hematopoietic stem cells. At: www.nsbri.org
- Harris I. (1994). The Laboratory Rabbit. *ANZCCART News*, Vol 7, No 4.

- IAEA (1971). Technical reports serie No.123, Manual on Radiation Haematology. International atomic energy agency, Vienna, Austria.
- Kauczor H., Dietal B., Brix G., Jarosch K. *et al.* (1993). Fatty replacement of bone marrow after radiation therapy for Hodgkin disease: quantification with chemical shift imaging. *J. Magn. Reson. Imaging.*, **3**: 575-580.
- Kaul A., Dehos A., Bogl W., Hinz G., Kossel F., Schwarz E.R., Stamm A., Stephan G. (1986). Biological Indicators for Radiation Dose Assessment. pp: 123-152.
- Kugel H., Jung C., Schulte O., Heindel W. (2001). Age and sex-specific differences in the ¹H-spectrum of vertebral bone marrow. *J. Magn. Reson. Imaging*, **13**: 263-8.
- Lecouvet F.E., Dechambre S., Malghem J., Ferrant A., Vande Berg B.C., Maldague B. (2001). Bone marrow transplantation in patients with multiple myeloma: prognostic significance of MR imaging. *Am. J. Roentgenol.*, **176**: 91-6.
- Li X., Wang C., Zhou Y. (1999). MR evaluation: spine changes after radiotherapy. *J. Tongji. Med. Univ.*, **19**: 72-6.
- Linden A., Zankovich R., Theissen P., Diehl V., Schicha H. (1989). Malignant lymphoma: bone marrow imaging versus biopsy. *Radiology*, **173**: 335-9.
- Iizuka M., Nagai K., Sugihara T., Tamada T., Imai S., Kojo T., Kajihara Y., Fukunaga M. (2001). Whole-body MR Imaging for Evaluation of Bone Marrow Cellularity in Aplastic Anemia. *Nippon Acta Radiologica*, **61**: 502-507.
- Mirowitz S., Apicella P., Reinus W.R., Hammerman A.M. (1994). MR imaging of bone marrow lesions: Relative conspicuousness on T1-weighted, fat-suppressed T2-weighted, and STIR images. *Am. J. Roentgenol.*, **162**: 215.
- Moulopoulos L.A., Varma D.G.K., Dimopoulos M.A., *et al.* (1992). Multiple myeloma: spinal MR imaging in patients with untreated newly diagnosed disease. *Radiology*, **185**: 833-40.
- Moulopoulos L.A., Dimopoulos M.A. (1997). Magnetic resonance imaging of the bone marrow in hematologic malignancies. *Blood*, **90**: 2127-2147.
- Negendank W., Weissman D., Bey T.M. *et al.* (1991). Evidence for clonal disease by magnetic resonance imaging in patients with hypoplastic marrow disorders. *Blood*, **11**: 2872-9.
- Onu M., Savu M., Lungu-Solomonescu C., Harabagiu I., Pop T. (2001). Early MR changes in vertebral bone marrow for patients following radiotherapy. *Eur. Radiol.*, **11**: 1463-9.
- Parmentier C., Morardent N., Schlumberger M. *et al.* (1985). Erythropoietic recovery in human after extended field radiotherapy. *Radiother. Oncol.*, **3**: 257-265.
- Pereira P.L., Schick F., Einsele H., Farnsworth C.T., Kollmansberger C., Mattke A., Duda S.H., Claussen C.D. (1999). MR tomography of the bone marrow changes after high-dosage chemotherapy and autologous peripheral stem-cell transplantation. *Rofo. Fortschr. Geb. Rontgenstr. Neuen. Bildgeb. Verfahr.*, **170**: 251-7.
- Porter B.A., Shield A.F., Olson D.O. (1986). Magnetic resonance imaging of bone marrow disorders. *Radiol. Clin. North Am.*, **24**: 269-289.
- Ramsey R.G., Zacharias C.E. (1985). MR imaging of the spine after radiation therapy: easily recognizable effects. *Am. J. Roentgenol.*, **144**: 1131-1135.
- Ricci C., Cova M., Kang Y.S., *et al.* (1990). Normal age-related patterns of cellular and fatty bone marrow distribution in the axial skeleton: MR imaging study. *Radiology*, **177**: 83-8.
- Rosen B.R., Feleming D.M., Kushner D.C., Zener K.S., Buxton R.B., Bennet W.P., Wismer G.L., Brady T.J. (1988). Hematologic bone marrow disorders: quantitative chemical shift MR imaging. *Radiology*, **169**: 799-804.
- Rozman M., Mercader J.M, Aguilar J.L,

- Montserrat E., Rozman C. (1997). Estimation of bone marrow cellularity by means of vertebral magnetic resonance. *Haematologica*, **82**: 166-170.
- Rosenthal D.I., Hayes C.W., Rosen B., Mayo-Smith W., Goodsitt M.M. (1989). Fatty replacement of spinal bone marrow due to radiation: demonstration by dual energy quantitative CT and MR imaging. *J. Comput. Assist. Tomogr.*, **13**: 463-465.
- Sabin F.R., Miller F.R., Smithburn K.C., Thomas R.M., Hummel L. E. (1936). Changes in the bone marrow and blood cells of developing rabbits. *J. Exp. Med.*, **67**: 97-120.
- Sacks E.L., Goris M.L., Glatstein E., Gilbert E., Kaplan H.S. (1978). Bone marrow regeneration following large field radiation. *Cancer*, **42**: 1057-1065.
- Shen W.C., Chen C.C., Chiang C.M., Liu C.K., Lee S.K., Lin J.C., Jan J.S. (1994). MR imaging evaluation of bone marrow signal change in post-irradiation patients with nasopharyngeal carcinoma. *Zhonghua Yi Xue Za Zhi (Taipei)*, **53**: 208-1
- Shields A.F., Porter B.A., Churchley S., Olson D.O., Appelbaum F.R., Thomas E.D. (1987). The detection of bone marrow involvement by lymphoma using magnetic resonance imaging. *J. Clin. Oncol.*, **5**: 225-30.
- Starz I., Einspieler R., Poschauko H., Ebner F., Arian-Schad K., Justich E. (1990). MR study of bone marrow changes of the spine following radiotherapy. *Rontgenblatter*, **43**: 355-8.
- Steiner R.M., Mitchell D.G., Rao V.M., et al. (1990). Magnetic resonance imaging of bone marrow: diagnostic value in diffuse hematologic disorders. *Magn. Reson. Q.*, **6**: 17-34.
- Steiner R.M., Mitchell D.G., Rao V.M., Schweitzer M.E. (1993). Magnetic resonance imaging of diffuse bone marrow disease. *Radiol. Clin. North. Am.*, **31**: 383-409.
- Stevens S.K., Moore S.G., Kaplan I.D. (1990). Early and late bone-marrow change after irradiation: MR evaluation. *Am. J. Roentgenology*, **154**: 745-750.
- Sugimura H., Kisanuki A., Tamura S., Kihara Y., Watanabe K., Sumiyoshi A. (1994). Magnetic resonance imaging of bone marrow changes after irradiation. *Invest. Radiol.*, **29**: 35-41.
- Tong X.Q., Sugimura H., Kisanuki A., Asato M., Yuki Y., Tamura S., Watanabe K. (1998). Multiple fractionated and single-dose irradiation of bone marrow. Evaluation by MR and correlation with histopathological findings. *Acta. Radiol.*, **39**: 620-4.
- Vande Berg B.C., Michaux L., Scheiff J.M. et al. (1996). Sequential quantitative MR analysis of bone marrow: differences during treatment of lymphoid versus myeloid leukemia. *Radiology*, **201**: 519-23.
- Volger J.B., Murphy W.A. (1988). Bone marrow Imaging. *Radiology*, **168**: 679-693.
- Yam L.T., Li C.Y., Crosby W.H. (1971). Cytochemical identification of monocytes and granulocytes. *Am. J. Clin. Patol.*, **55**: 283-290.
- Yankelevitz D.F., Henschke C.I., Knapp P.H., Nisce L., Yi Y., Cahill P. (1991). Effect of radiation therapy in thoracic and lumbar marrow: evaluation with MR imaging. *Am. J. Roentgenol.*, **157**: 87-92.
- Yoffey J.M. and Parnell J. (1944). The lymphocyte content of rabbit bone marrow. *J. Anat.*, **78**: 109-112.